


# Journal Pre-proof



Factors affecting volume change of the anterolateral thigh flap in head and neck defect reconstruction

Shun-Ji Wang, M.D., Resident, Wen-Bo Zhang, M.D., Attending Doctor, Yao Yu, M.D., Resident, Tai Wang, M.D., Associate Senior Doctor, Hong-Yu Yang, M.D., Professor, Xin Peng, M.D., D.D.S., Professor

PII: S0278-2391(20)30592-9

DOI: <https://doi.org/10.1016/j.joms.2020.06.017>

Reference: YJOMS 59273

To appear in: *Journal of Oral and Maxillofacial Surgery*

Received Date: 9 March 2020

Revised Date: 9 June 2020

Accepted Date: 9 June 2020

Please cite this article as: Wang S-J, Zhang W-B, Yu Y, Wang T, Yang H-Y, Peng X, Factors affecting volume change of the anterolateral thigh flap in head and neck defect reconstruction, *Journal of Oral and Maxillofacial Surgery* (2020), doi: <https://doi.org/10.1016/j.joms.2020.06.017>.

This is a PDF file of an article that has undergone enhancements after acceptance, such as the addition of a cover page and metadata, and formatting for readability, but it is not yet the definitive version of record. This version will undergo additional copyediting, typesetting and review before it is published in its final form, but we are providing this version to give early visibility of the article. Please note that, during the production process, errors may be discovered which could affect the content, and all legal disclaimers that apply to the journal pertain.

© 2020 Published by Elsevier Inc on behalf of the American Association of Oral and Maxillofacial Surgeons

## **Factors affecting volume change of the anterolateral thigh flap in head and neck defect reconstruction**

Shun-Ji Wang, M.D., Resident<sup>1</sup>; Wen-Bo Zhang, M.D., Attending Doctor<sup>1</sup>; Yao Yu, M.D., Resident<sup>1</sup>; Tai Wang, M.D., Associate Senior Doctor<sup>2</sup>; Hong-Yu Yang, M.D., Professor<sup>3</sup>; Xin Peng\*, M.D., D.D.S., Professor<sup>1</sup>

1. Department of Oral and Maxillofacial Surgery, Peking University School and Hospital of Stomatology; Beijing.

2. Department of Oral and Maxillofacial Surgery, Yinchuan Stomatology Hospital; Ningxia.

3. Department of Oral and Maxillofacial Surgery, Peking University Shenzhen Hospital; Shenzhen.

### **\*Corresponding author**

Xin Peng, M.D., D.D.S.

Department of Oral and Maxillofacial Surgery, Peking University School and Hospital of Stomatology, 22# Zhongguancun South Avenue, Beijing 100081, China.

Tel: +86 010 82195210

Fax: +86 010 82195210

E-mail: [pxpengxin@263.net](mailto:pxpengxin@263.net)

**Abstract:**

**Purpose:** The anterolateral thigh flap (ALTF) volume decreases over time following surgery. We aimed to measure and identify risk factors for postoperative volume change of the ALTF.

**Methods:** We designed and performed a retrospective cohort study of patients who underwent reconstruction of oral and maxillofacial defects using ALTFs at the Department of Oral and Maxillofacial Surgery, Peking University School and Hospital of Stomatology, between June 2012 and December 2018. We measured the volume of the ALTFs at 1, 3, 6, 12 and 24 months postoperatively; the flap volume 1 month postoperatively was the baseline. The primary outcome variables were the residual rates of ALTFs at 3, 6, 12, and 24 months postoperatively, which were defined as the ratios between the present volume of each month and the baseline. The primary predictor variables were clinical variables that may be associated with ALTFs volume loss. Descriptive and bivariate statistics were computed and the *P*-value was set at 0.05.

**Results:** The sample was composed of 70 subjects with a mean age of 53.8 years (46 males and 24 females). The postoperative residual rates at 3, 6, 12, and 24 months were 72.3, 69.0, 67.9, and 68.7%, respectively, of the baseline volume. Postoperative radiotherapy ( $P < 0.01$ ) and BMI ( $P = 0.006$ ) were significantly inversely associated with postoperative ALTF volume loss.

**Conclusion:** The results of this study suggest that ALTF volume shrinkage mainly developed within 6 months postoperatively, postoperative radiotherapy and BMI were

the risk factors. Overcorrection should be performed to account for the shrinkage of ALTFs, and postoperative nutrition management is important to avoid ALTF volume loss.

**Key words:** Anterolateral thigh flap, Oral and maxillofacial defect, Volume change, Risk factors, Head and neck.

## Introduction

Simultaneous reconstruction for extensive tissue defects after tumor ablation is recommended to minimize functional and esthetic problems in cases undergoing oral and maxillofacial surgery [1, 2]. With tremendous improvements made in microsurgical techniques and instruments over the past 3 decades, free flap transfer has become a standard and reliable approach for oral and maxillofacial defect reconstruction [2-6]. Due to its many advantages, such as consistent anatomy of the main pedicle and variable thickness and volume can be supplied based on the defect extent, the anterolateral thigh flap (ALTF) has become increasingly popular among surgeons since it was described in 1984 by Song et al. [7], is being regarded as a versatile flap for the reconstruction of oral and maxillofacial defects by some surgeons [8-13].

A soft tissue flap with appropriate volume is crucial for the functional and esthetic outcomes in oral and maxillofacial defect reconstruction [2, 14-16]. However, postoperative ALTF volume loss is commonly observed in clinical practice [17-19], which can markedly affect the speech, swallowing, and patient appearance [14, 16]. Therefore, a flap larger than the actual defect may be required to compensate for the atrophy of the flap itself.

Although a few studies have reported on the postoperative volume change of ALTFs and the relevant risk factors, unanimous consensus still has not been reached [17-19]. To our knowledge, no research with a large sample size has been conducted

with long-term continuous follow-up regarding the postoperative volume change of ALTFs. The purpose of this study was to measure and identify risk factors associated with postoperative volume changes of ALTFs. The investigators hypothesized that postoperative ALTF volume decreased over time and some clinical factors were risk factors. The specific aims of the study were to estimate the continuous volume change of the ALTF and identify the risk factors.

## **Materials and methods**

### **Study design**

To address the research purpose, the investigators designed and performed a retrospective cohort study. The study population was composed of patients who underwent reconstruction of oral and maxillofacial defects using ALTFs at the Department of Oral and Maxillofacial Surgery, Peking University School and Hospital of Stomatology, between June 2012 and December 2018. All the surgeries were performed by a single surgical team. To be included in the study sample, patients had to: (1) undergo reconstruction of oral and maxillofacial defects using ALTFs, (2) age  $\geq 18$  years, (3) ALTFs harvested without muscular component, (4) available postoperative computed tomography, and (5) no sign of regional infection with clinical examination and on the CT scan at 1 month postoperatively. Patients were excluded as study subjects if: (1) reconstruction was performed using other kinds of flap besides the ALTF simultaneously, (2) local recurrence occurred during the follow-up period, or (3) secondary reconstruction or excisional correction of the flap was performed.

### **Measurement procedure**

Routine CT scans of the head and neck region were performed at 1, 3, 6, 12, and 24 months postoperatively (field of view, 20 cm; pitch, 1.0; slice, 1.25 mm; 120Y280 mA), and the CT data was imported to the iPlan CMF 3.0.5 software (BrainLAB, Feldkirchen, Germany) in the DICOM format. First, the border of the flap on each axial image was manually traced in iplan CMF 3.05. Then, the software could automatically generate the three-dimensional model and calculate the flap volume (Figure 1). Each of the CT data was measured by two doctors (interclass correlation coefficient = 0.98) and the mean value was adopted, in cases where the difference between the measurements was > 10%, an additional measurement was obtained and the mean value was calculated. Using the 1-month postoperative volume as the baseline, the residual rates of the ALTFs at 3, 6, 12, and 24 months postoperatively were calculated.

### **Study variables**

Clinical factors that may be associated with the postoperative volume change of ALTFs were examined as possible predictors, including: (1) demographic factors: age and gender, (2) factors associated with the patient's general condition and personal history: diabetes mellitus(DM), hypertension, body mass index (BMI,  $\text{kg/m}^2$ ), smoking status, and alcohol consumption, (3) treatment factors: primary sites, history of surgery in the oral and maxillofacial region, postoperative radiotherapy, and postoperative chemotherapy.

We measured the volume of the ALTFs at 1, 3, 6, 12 and 24 months

postoperatively. The flap volume at the 1 month postoperatively was set as the baseline, and we defined the “postoperative residual rate” as the ratio between the present volume of each month and the baseline. The primary outcome variables were postoperative residual rates at 3, 6, 12, and 24 months.

### **Statistical analysis**

The paired samples t-test was used to evaluate the ALTF volume change over time. The independent samples t-test was used to evaluate the influence of gender, systematic diseases, smoking status, alcohol consumption, history of surgery, radiotherapy and chemotherapy on flap volume loss. Different groups of age, primary site, and BMI were examined using one-way analysis of variance (ANOVA). Factors with  $P$ -value  $< 0.05$  were included in multiple linear regression models to identify the significant risk factors associated with volume loss of ALTFs. Statistical analysis was performed using SPSS version 22.0 software (SPSS, Chicago, USA). Statistical significance was considered if the  $P$ -value was  $< 0.05$ .

This study was approved by the Ethical Review Board of Peking University School and Hospital of Stomatology (PKUSSIRB-201945068). All procedures conformed to the tenets of the Helsinki Declaration.

### **Results**

A total of 70 patients were included in this retrospective study. Among these patients, 46 were males and 24 were females, their mean age was 53.8 years old (range, 19-79 years). The primary site was the tongue in 8, the buccal mucosa in 5, the maxilla in 44, the mandible in 6, and other sites in 7 patients. The histopathological



diagnosis was squamous cell carcinoma in 41, adenoid cystic carcinoma in 6, mucoepidermoid carcinoma in 3, sarcoma in 4, and other diagnoses in 16 patients. The clinical characteristics and information of these patients were summarized in Table 1.

The mean follow-up duration was 16.8 months (range, 12-65 months). All patients had CT data available for both 1 and 12 months postoperatively, and 23 of the patients had consecutive CT data available, including data at 1, 3, 6, and 12 months postoperatively. In the present study, we analyzed the continuous volume change among these 23 patients, and identified the risk factors in all the 70 patients.

Among the 23 patients with consecutive CT data, the mean residual rates of the ALTFs at 3, 6, and 12 months postoperatively were 72.3, 69.0, and 67.9%, respectively. The residual rates at 3 and 6 months postoperatively were significantly different ( $P = 0.022$ ), although those at 6 and 12 months postoperatively did not significantly differ ( $P = 0.441$ ; Figure 2).

A total of 16 patients were followed-up over 24 months postoperatively, and the mean residual rates at 12 and 24 months postoperatively were 70.9 and 68.7%, respectively, but the difference was not significant ( $P = 0.622$ ).

Single factors analysis showed that the residual rates at 12 months postoperatively significantly differed between patients with adjuvant radiotherapy and without radiotherapy ( $P < 0.01$ ) (Figure 3). We categorized patients based on their BMI (group A:  $\text{BMI} < 18.5 \text{ kg/m}^2$ ; group B:  $18.5 \text{ kg/m}^2 \leq \text{BMI} < 25 \text{ kg/m}^2$ ; group C:  $\text{BMI} \geq 25 \text{ kg/m}^2$ ), and marked differences in residual rates at 12 months

postoperatively were noted between group A and group C ( $P = 0.003$ ) and between group B and group C ( $P = 0.045$ ). However, the difference in residual rates at 12 months postoperatively between group A and group B ( $P = 0.054$ ) was not significant. Overall, the difference in residual rates at 12 months postoperatively was significant for BMI ( $P = 0.009$ ) (Figure 4). No correlation was observed between ALTF volume change at 12 months postoperatively and age ( $P = 0.624$ ), gender ( $P = 0.879$ ), smoking status ( $P = 0.141$ ), alcohol consumption ( $P = 0.110$ ), DM ( $P = 0.326$ ), hypertension ( $P = 0.931$ ), primary sites ( $P = 0.684$ ), surgery history ( $P = 0.402$ ), or chemotherapy ( $P = 0.236$ ) (Table 2).

Thus, radiotherapy and BMI were included in multiple linear regression models, and the result showed that both radiotherapy ( $P < 0.01$ ) and BMI ( $P = 0.006$ ) were both significantly associated with volume loss of ALTFs (Table 3).

## Discussion

Although a few studies have reported on the volume change of the soft tissue flap following reconstruction of the oral and maxillofacial region [17-22], no consensus has been reached by far. Most of these studies have certain limitations, such as the estimation of flap volume using two-dimensional techniques, small sample sizes, and short-term follow-up duration. The purpose of this study was to assess the postoperative three-dimensional volume changes of ALTFs and identify the independent risk factors. The investigators hypothesized that postoperative ALTF volume decreased over time and some clinical factors were the risk factors. The specific aims of the study were to estimate the continuous volume change of ALTF

and identify the risk factors. We found that postoperative radiotherapy and BMI were risk factors for postoperative volume loss of ALTF.

The result of this study showed that most of the ALTFs volume shrinkage occurred within the 6 months after reconstruction, particularly within the first 3 months, with an overall residual rate of 72.3% at 3 months and 69.0% at 6 months postoperatively, the difference between the volume at 3 and 6 months postoperatively was significantly different ( $P = 0.022$ ). The residual rate at 12 months postoperatively was almost 67.9%, and did not significantly differ from that at 6 months postoperatively ( $P = 0.441$ ). The long-term follow-up of 16 patients showed a small amount of volume loss between 12 and 24 months, with an overall residual rate of 68.7% at 24 months postoperatively; however, the difference in the residual rates between 12 and 24 months postoperatively did not significantly differ ( $P = 0.622$ ).

Overall, the volume change of the ALTFs in the present study is similar to that reported in a previous study. In that study, Tarsitano et al. [19] assessed 20 patients who underwent reconstruction using ALTFs, and reported an average residual rate of 65.3% at 12 months postoperatively. Cho et al. [18] reported residual rates of ALTFs at 12 and 24 months postoperatively were 79.1 and 75.2%, respectively, which were more than those reported in the present study. We think one of the possible reasons for this difference is that Cho et al. used the 3-month postoperative volume as the baseline, whereas our findings indicated marked volume loss within the first 3 months postoperatively. In a study of 13 patients who underwent total parotidectomy reconstruction with ALTFs, Higgins et al. [23] reported a mean residual rate of 91.9%

after radiotherapy. Moreover, Yamaguchi et al. [20] reported an overall residual volume of 82.2% for free flaps at 28.9 months postoperatively (range, 2.1-48.4 months).

In the present study, the residual rates of the irradiated flaps and non-irradiated flaps at 12 months postoperatively were 57.0 and 76.8%, respectively, and the difference was significant ( $P < 0.01$ ). In a long-term retrospective study of 16 patients who underwent radial forearm free flap reconstruction, Joo et al. [24] reported that a significant relationship was present between postoperative irradiation and volume change of the flap ( $P = 0.046$ ). Tarsitano et al. [19] also indicated that postoperative radiotherapy was a risk factor of postoperative volume change of ALTFs ( $P = 0.041$ ). However, Kimura et al. [17, 18, 25, 26] reported that postoperative adjuvant irradiation had no significant effect on the volume change of flaps in oral and maxillofacial reconstruction ( $P > 0.05$ ).

Although the effect of postoperative adjuvant radiotherapy on free flaps remains controversial, the current study indicated that postoperative radiotherapy was risk factor for ALTF volume loss. Sun et al. [27] used transmission electron microscope to observe the damage of soft tissue caused by radiotherapy, and found that radiotherapy could cause direct damage to cells, resulting in decrease of cell composition and increase of collagen. A large amount of collagen fibrils was deposited in extracellular matrix, further organization and soft tissue fibrosis occurred. In addition, collagen fibrils was found in the vascular lumen of soft tissue after radiotherapy, which could cause serious changes of blood vessels, such as destruction of blood vessel wall and

thrombosis, and then affect the blood supply of soft tissue. We suppose that the soft tissue fibrosis and disturbance of blood supply caused by radiotherapy were the main reasons of ALTFs volume loss.

This study indicated that the difference between residual rates at 12 months postoperatively among groups with different BMI was significant ( $P = 0.006$ ). The weight of patients was lighter in group A, normal in group B, and overweight in group C. The result indicated that residual rates of ALTFs of overweight patients were higher than those of patients with normal and lighter weight, and the ALTF volume loss was less for overweight patients. Several previous studies had indicated the importance of nutritional management for avoiding reduction in flap volume. Kimura et al. [17] reported that weight loss was a risk factor for flap atrophy. Hiraki et al. [28] measured the albumin levels at 6 and 12 months postoperatively, and found that the values significantly differed both at 6 ( $P = 0.026$ ) and 12 months ( $P = 0.017$ ). However, Sakamoto et al.[1] reported that the BMI and postoperative albumin levels were not associated with flap volume changes (BMI:  $P = 0.540$ ; albumin levels:  $P = 0.612$ ).

The volume of fat cells of overweight patients are larger than those of patients with normal and lighter weight [29], and we speculate difference in structure of fat tissue results in the different shrinkage of ALTF. Generally, the head and neck reconstruction surgery certainly have influence on nutrition intake of the patients postoperatively, which will result in the loss of weight. But nutrition intake increases with the recovery of swallowing function and thus weight will increase after surgery

for some patients. And we found that the ALTF volume increased along with the weight increasing in certain patients. Considering BMI is an important index for the nutrition status of patients, we advise to strengthen the postoperative nutrition management, so that to reduce the loss of flap volume.

To our knowledge, no previous study has reported the effect of postoperative chemotherapy on the volume change of ALTFs. In this study, 15 patients received adjuvant chemotherapy, and the residual rate at 12 months postoperatively was 64.2%; whereas, in patients who did not receive adjuvant chemotherapy, the residual rate was 71.6%, the difference was not significant ( $P = 0.236$ ).

In the present study, we did not find any correlation between age, gender, systematic diseases, smoking status, alcohol consumption, primary sites, history of surgery in the oral and maxillofacial region and volume change of ALTF after surgery ( $P > 0.05$ ). Cho et al. [18] also reported that age, gender, systematic diseases, smoking status, and alcohol consumption were not associated with the volume change of free flaps. However, in a retrospective study of 30 patients, Hiraki et al. [28] reported that hypertension and DM were significantly correlated with the volume change at 6 months postoperatively (hypertension:  $P = 0.016$ ; DM:  $P = 0.006$ ), whereas no association was noted at 12 months postoperatively (hypertension:  $P = 0.076$ ; DM:  $P = 0.155$ ). Sakamoto et al. [1] reported that renal failure ( $P = 0.001$ ) and previous history of surgery in the oral region ( $P = 0.013$ ) were risk factors for volume loss of myocutaneous flap.

To summarize, ALTF volume shrinkage mainly developed within 6 months

postoperatively, postoperative radiotherapy and BMI were the risk factors. Overcorrection should be performed to account for the shrinkage of ALTFs, and postoperative nutrition management is important to avoid postoperative ALTF volume loss.

The present study is a retrospective study with a relatively large sample size, and we continuously monitored the volume change of ALTFs postoperatively using three-dimensional imaging techniques. Compared to flap volume estimation with two-dimensional techniques, three-dimensional imaging technology enables three-dimensional visualization, which is more accurate and objective. In particular, we assessed the relationship between postoperative chemotherapy and ALTF volume change, which to our knowledge has not been previously elucidated. However, the present study has certain limitations. For example, we did not record the BMI of each patient at every postoperative time point, further study is necessary to identify the relationship between BMI change and ALTF volume change.

## **Conclusion**

The results of this study suggest that ALTF volume shrinkage mainly developed within 6 months postoperatively, postoperative radiotherapy and BMI were the risk factors. Overcorrection should be performed to account for the shrinkage of ALTFs, and postoperative nutrition management is important to avoid ALTF volume loss.

## **Conflicts of interests**

The authors have no financial interest in any of the products or devices mentioned in this article.

## Financial Disclosure Statement

This work was supported by the Key Research and Development Program of Ningxia Hui Autonomous Region (2018BEG02012).

## Ethical approval

Ethical approval was obtained from the Biomedical Institutional Review Board of Peking University School and Hospital of Stomatology (PKUSSIRB-201945068).

## Acknowledgement

We thank the professional editor of Elixigen Company for revising and modifying the English language of this manuscript.

## References

1. Sakamoto Y, Yanamoto S, Ota Y, Furudoi S, Komori T, Umeda M: Magnitude of Myocutaneous Flaps and Factors Associated With Loss of Volume in Oral Cancer Reconstructive Surgery. *J Oral Maxillofac Surg* 74:644, 2016
2. Lam L, Samman N: Speech and swallowing following tongue cancer surgery and free flap reconstruction--a systematic review. *Oral Oncol* 49:507, 2013
3. Nakatsuka T, Harii K, Asato H, Takushima A, Ebihara S, Kimata Y, Yamada A, Ueda K, Ichioka S: Analytic review of 2372 free flap transfers for head and neck reconstruction following cancer resection. *J Reconstr Microsurg* 19:363, 2003
4. Eckardt A, Fokas K: Microsurgical reconstruction in the head and neck region: an 18-year experience with 500 consecutive cases. *J Craniomaxillofac Surg* 31:197, 2003
5. Kim EK, Evangelista M, Evans GR: Use of free tissue transfers in head and neck reconstruction. *J Craniofac Surg* 19:1577, 2008
6. Steel BJ, Cope MR: A brief history of vascularized free flaps in the oral and maxillofacial region. *J Oral Maxillofac Surg* 73:786 e1, 2015
7. Song YG, Chen GZ, Song YL: The free thigh flap: a new free flap concept based on the septocutaneous artery. *Br J Plast Surg* 37:149, 1984
8. de Vicente JC, de Villalain L, Torre A, Pena I: Microvascular free tissue transfer for tongue reconstruction after hemiglossectomy: a functional assessment of radial forearm versus anterolateral thigh flap. *J Oral Maxillofac Surg* 66:2270, 2008
9. Wei FC, Jain V, Celik N, Chen HC, Chuang DC, Lin CH: Have we found an ideal soft-tissue flap? An experience with 672 anterolateral thigh flaps. *Plast Reconstr Surg* 109:2219, 2002
10. Hanasono MM, Skoracki RJ, Yu P: A prospective study of donor-site morbidity after



anterolateral thigh fasciocutaneous and myocutaneous free flap harvest in 220 patients. *Plast Reconstr Surg* 125:209, 2010

11. Revenaugh PC, Haffey TM, Seth R, Fritz MA: Anterolateral thigh adipofascial flap in mucosal reconstruction. *JAMA Facial Plast Surg* 16:395, 2014

12. Wolff KD, Kesting M, Thurmuller P, Bockmann R, Holzle F: The anterolateral thigh as a universal donor site for soft tissue reconstruction in maxillofacial surgery. *J Craniomaxillofac Surg* 34:323, 2006

13. Engel H, Huang JJ, Lin CY, Lam W, Kao HK, Gazyakan E, Cheng MH: A strategic approach for tongue reconstruction to achieve predictable and improved functional and aesthetic outcomes. *Plast Reconstr Surg* 126:1967, 2010

14. Yun IS, Lee DW, Lee WJ, Lew DH, Choi EC, Rah DK: Correlation of neotongue volume changes with functional outcomes after long-term follow-up of total glossectomy. *J Craniofac Surg* 21:111, 2010

15. Matsui Y, Shirota T, Yamashita Y, Ohno K: Analyses of speech intelligibility in patients after glossectomy and reconstruction with fasciocutaneous/myocutaneous flaps. *Int J Oral Maxillofac Surg* 38:339, 2009

16. Rhemrev R, Rakhorst HA, Zuidam JM, Mureau MA, Hovius SE, Hofer SO: Long-term functional outcome and satisfaction after radial forearm free flap reconstructions of intraoral malignancy resections. *J Plast Reconstr Aesthet Surg* 60:588, 2007

17. Kimura M, Takada K, Ishibashi K, Ohto H, Shibata A, Yamada H, Nishiwaki S, Naganawa Y, Umemura M: Quantitative analysis of chronological changes in the volume of flaps used for reconstruction of oral cavity defects. *J Oral Sci* 59:499, 2017

18. Cho KJ, Joo YH, Sun DI, Kim MS: Perioperative clinical factors affecting volume changes of reconstructed flaps in head and neck cancer patients: free versus regional flaps. *Eur Arch Otorhinolaryngol* 268:1061, 2011

19. Tarsitano A, Battaglia S, Cipriani R, Marchetti C: Microvascular reconstruction of the tongue using a free anterolateral thigh flap: Three-dimensional evaluation of volume loss after radiotherapy. *J Craniomaxillofac Surg* 44:1287, 2016

20. Yamaguchi K, Kimata Y, Onoda S, Mizukawa N, Onoda T: Quantitative analysis of free flap volume changes in head and neck reconstruction. *Head Neck* 34:1403, 2012

21. Fujioka M, Masuda K, Imamura Y: Fatty tissue atrophy of free flap used for head and neck reconstruction. *Microsurgery* 31:32, 2011

22. Eskander A, Enepekides D, Higgins K: Colour Doppler and volume changes-anterolateral thigh flap: the sunnybrook experience. *ISRN Surg* 2011:241385, 2011

23. Higgins KM, Erovic BM, Ravi A, Yeung R, Lee JW, Yao C, Enepekides DJ: Volumetric changes of the anterolateral thigh free flap following adjuvant radiotherapy in total parotidectomy reconstruction. *Laryngoscope* 122:767, 2012

24. Joo YH, Hwang SH, Sun DI, Park JO, Cho KJ, Kim MS: Assessment of volume changes of radial forearm free flaps in head and neck cancer: long-term results. *Oral Oncol* 47:72, 2011

25. Chatterjee JS, Lee A, Anderson W, Baker L, Stevenson JH, Dewar JA, Thompson AM: Effect of postoperative radiotherapy on autologous deep inferior epigastric perforator flap volume after immediate breast reconstruction. *Br J Surg* 96:1135, 2009

26. Bittermann G, Thonissen P, Poxleitner P, Zimmerer R, Vach K, Metzger MC: Microvascular transplants in head and neck reconstruction: 3D evaluation of volume loss. *J Craniomaxillofac*

Surg 43:1319, 2015

27. Sun YG, Sun KH, Wang GH: The ultrastructural study on radiation injuries of the jaws and soft tissues. *Chin J Stomatol* 31:147, 1996

28. Hiraki A, Yamamoto T, Yoshida R, Nagata M, Kawahara K, Nakagawa Y, Matsuoka Y, Tanaka T, Hirose A, Fukuma D, Ikebe T, Shinohara M, Nakayama H: Factors affecting volume change of myocutaneous flaps in oral cancer. *Int J Oral Maxillofac Surg* 45:1395, 2016

29. Yang YY, Hu CP: Obesity and adipose tissue remodeling. *Chinese Pharmacological Bulletin* 32:9, 2016

**Table 1.** Patient Characteristics

Characteristics	N or mean value	Percentage rate
Total	70	100%
Gender		
Male	46	65.7%
Female	24	34.3%
Age (years)	53.8 (19-79)	
Primary site		
Tongue	8	11.4%
Buccal mucosa	5	7.1%
Maxilla	44	62.9%
Mandible	6	8.6%
Others	7	10.0%
Histopathology		
SCC	41	58.6%
ACC	6	8.6%
Mucoepidermoid carcinoma	3	4.3%
Sarcoma	4	5.7%
Others	16	22.9%

SCC, squamous cell carcinoma; ACC, adenoid cystic carcinoma

**Table 2.** Univariate Analysis of Potential Influencing Factors for ALTF Volume Change

Characteristic	N	Residual rate	<i>P</i> -value
Total	70	70.0%	

Gender			0.879 <sup>a</sup>
Male	46	69.7%	
Female	24	70.6%	
Age (years)			0.624 <sup>b</sup>
< 45	19	74.1%	
45-60	20	68.9%	
≥ 60	31	68.2%	
Smoking status			0.141 <sup>a</sup>
Smoker	15	62.8%	
Non-smoker	55	72.0%	
Alcohol consumption			0.110 <sup>a</sup>
Drinker	8	58.7%	
Non-drinker	62	71.5%	
Diabetes mellitus			0.326 <sup>a</sup>
Yes	6	61.8%	
No	64	70.8%	
Hypertension			0.931 <sup>a</sup>
Yes	17	70.4%	
No	53	69.9%	
BMI (kg/m <sup>2</sup> )			0.009 <sup>b*</sup>
< 18.5	9	54.8%	
18.5 - 25	46	69.2%	
≥ 25	15	81.5%	
Primary site			0.684 <sup>b</sup>
Tongue	8	60.1%	
Buccal mucosa	5	66.8%	
maxilla	44	74.1%	
mandible	6	60.0%	
Others	7	66.7%	
History of surgery			0.402 <sup>a</sup>
Yes	18	73.7%	
No	52	68.7%	
Radiotherapy			< 0.001 <sup>a*</sup>
Yes	24	57.0%	
No	46	76.8%	
Chemotherapy			0.236 <sup>a</sup>
Yes	15	64.2%	
No	55	71.6%	

a Student t-test

b One-way analysis of variance

\*  $P < 0.05$

Table 3. Multiple Linear Regression of Influencing Factors for ALTF Volume Change

Characteristic	N	Residual rate	P-value
BMI (kg/m <sup>2</sup> )			0.006
< 18.5	9	54.8%	
18.5-25	46	69.2%	
≥ 25	15	81.5%	
Radiotherapy			< 0.001
Yes	24	57.0%	
No	46	76.8%	

**Figure legends:**

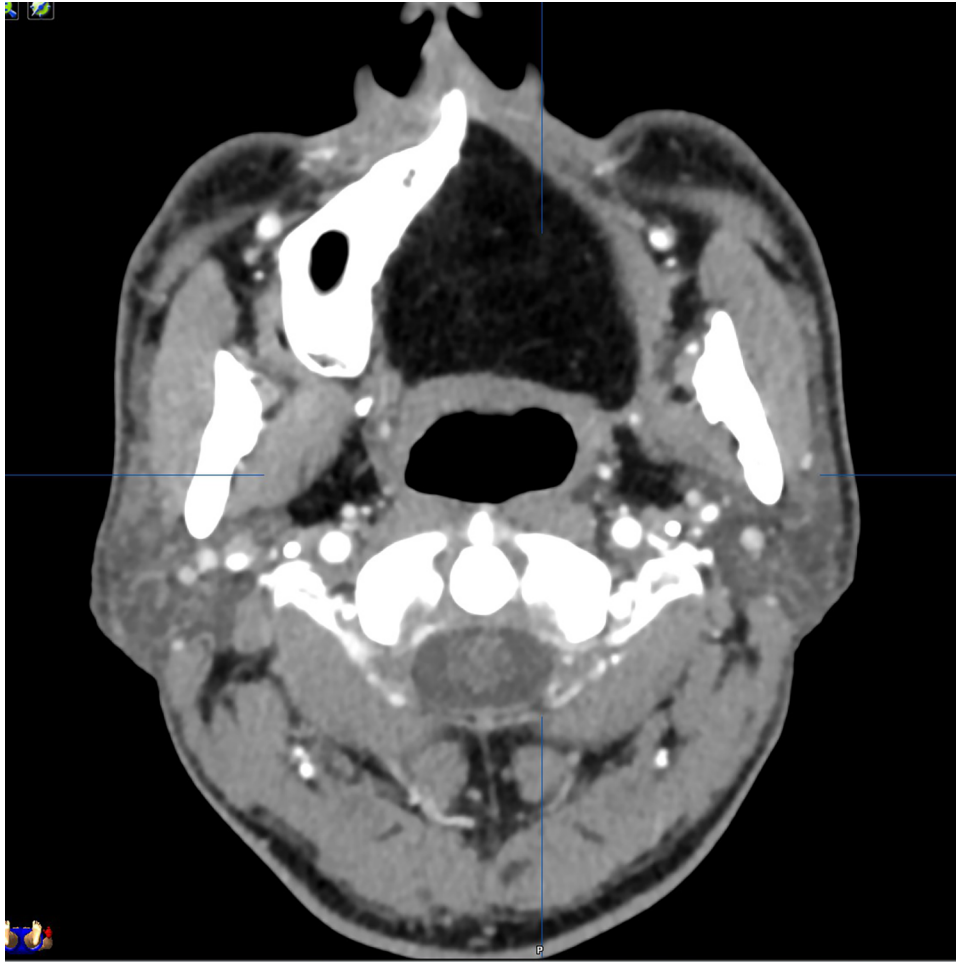
**Figure 1.** Computed tomography images contouring and three-dimensional reconstruction of an ALTF in a patient who was diagnosed with squamous cell carcinoma of the hard palate and underwent reconstruction after surgical resection. A: CT scan before contouring, B: axial image contouring, C: coronal image contouring, D: sagittal image contouring, E: 3-D reconstruction, F: automatic calculation of the flap volume.

**Figure 2.** Continuous volume change of ALTF postoperatively.

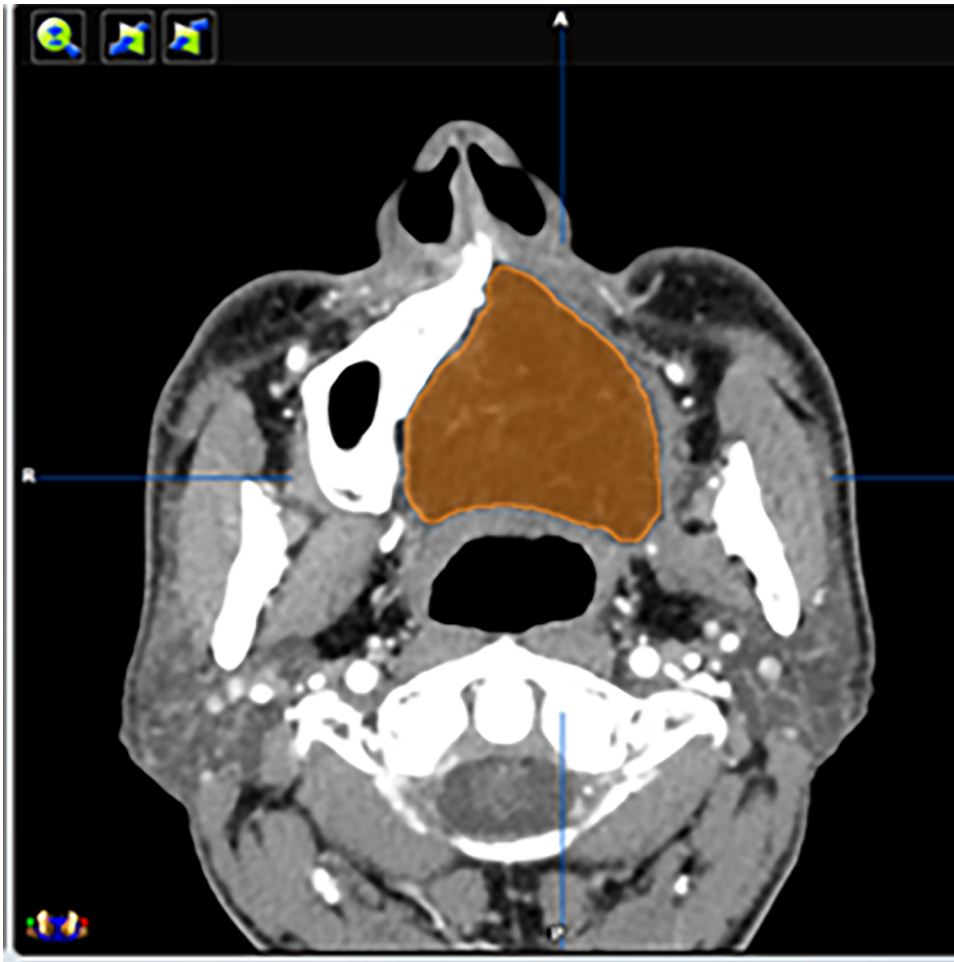
**Figure 3.** Residual rates of ALTF volume in patients with radiotherapy (n = 7) and without radiotherapy (n = 16).

**Figure 4.** Residual rates of ALTF volume in patients with different BMI.

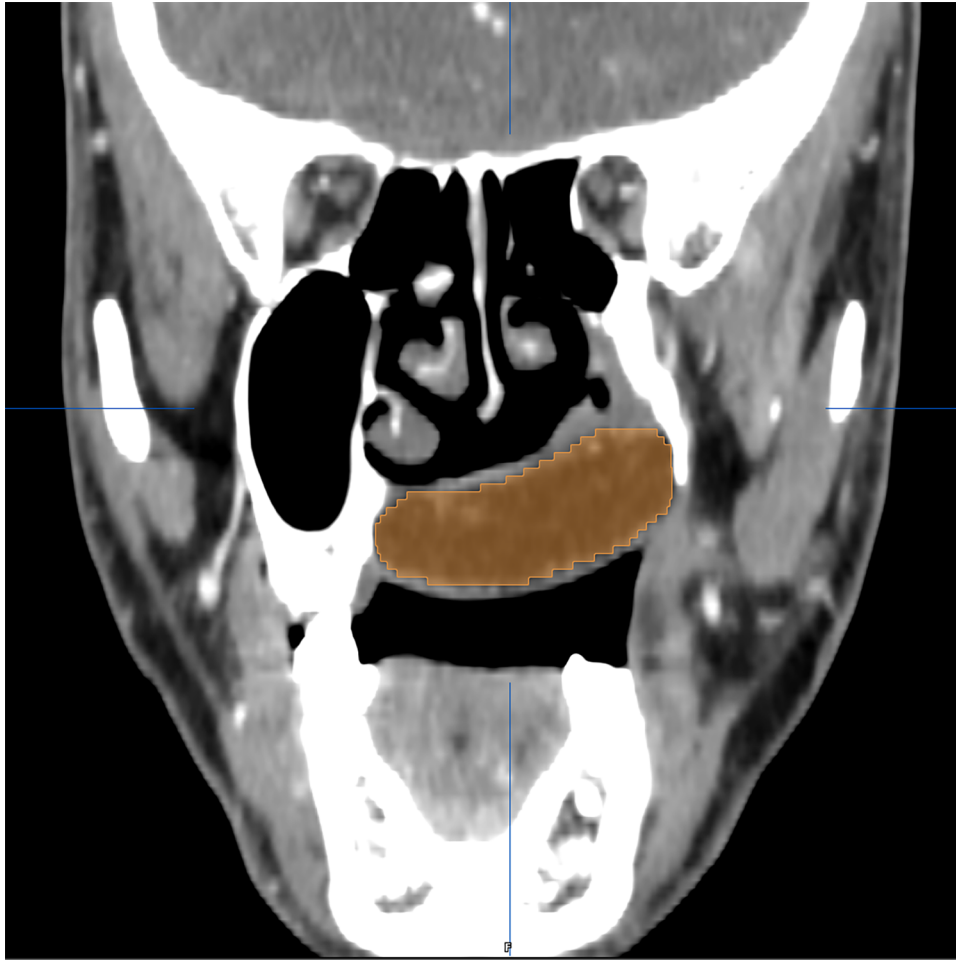Journal Pre-proof



Journal

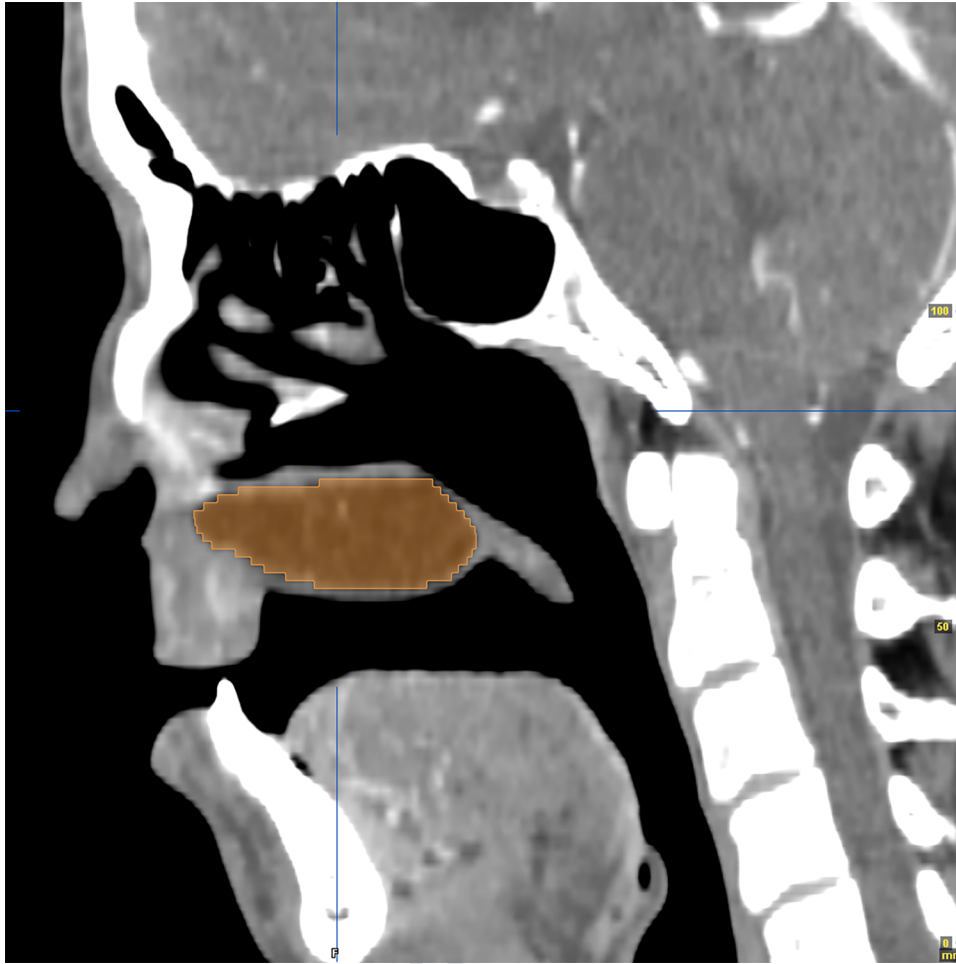

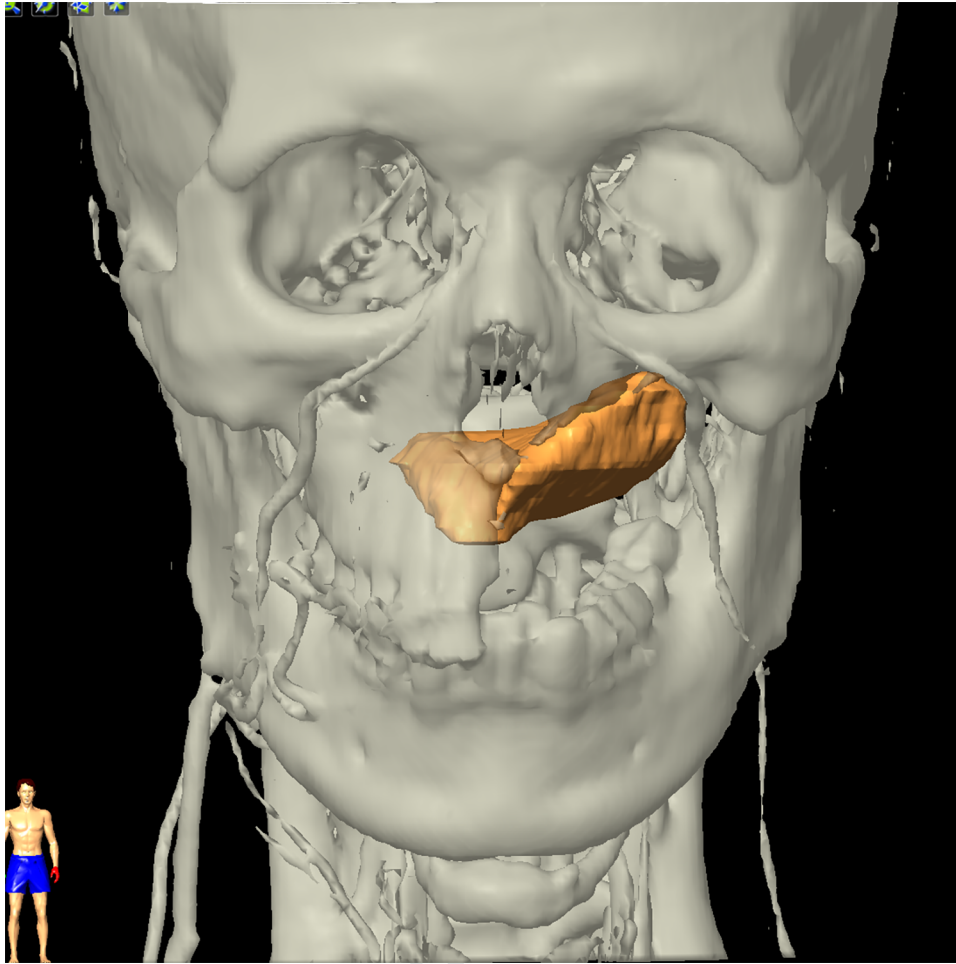
Journal



Journal








Journal

Patient: LI CUNGUI  
Treatment Plan: Default Plan Name

Image Sets  
#1 (CT; Axial)  
#2 (CT; Axial)  
#3 (CT; Axial)

Objects  
Tumor

Properties



Name: Tumor  
Image Set: #3 (CT; Axial)  
Volume: 21.916 cm<sup>3</sup>  
Slice Distance (mm): 1.250  
Pixel Size [w/h] (mm): 0.196 / 0.196

Volumetric Measurement

Image Set: #3 (CT; Axial)

Minimum Value: -142 HU  
Maximum Value: 180 HU  
Average Value: -89 HU  
Standard Deviation: 23.405

Copy to Clipboard

