



Recurrence-Related Factors of Medication-Related Osteonecrosis of the Jaw: A Five-Year Experience

Shuo Chen, DDS, MD, Hongyu Ren, DDS,† Yang He, DDS, MD,‡ Jingang An, DDS, MD,§ and Yi Zhang, PhD, MD, DDS||*

Purpose: The treatment of medication-related osteonecrosis of the jaw (MRONJ) is greatly challenging for surgeons. In this study, we reviewed patients with MRONJ treated in our hospital in the past 5 years and explored the risk factors of recurrence.

Methods: A retrospective cohort study was conducted to review the patients with MRONJ from January 1, 2016 to December 31, 2020. All patients received a monthly intravenous application of zoledronic acid. The primary outcome variable was the treatment outcome during follow-up. The predictor variables were local and systemic factors related to the treatment outcome. Multivariate logistic regression analysis was performed to identify the risk factors of recurrence after MRONJ treatment.

Results: A total of 58 patients (62 sites) were included in this study. In multivariate regression analysis, the risk factor associated with recurrence after MRONJ treatment was the duration of medication of more than 18 months (odds ratio = 7.346; 95% confidence interval: 1.461-36.946; $P = .016$).

Conclusions: Using zoledronic acid over 18 months may increase the risk of recurrence in MRONJ patients.

© 2021 The American Association of Oral and Maxillofacial Surgeons.
J Oral Maxillofac Surg 79:2472–2481, 2021

*Attending, Department of Oral and Maxillofacial Surgery, Peking University School and Hospital of Stomatology, National Center of Stomatology, National Clinical Research Center for Oral Diseases, National Engineering Laboratory for Digital and Material Technology of Stomatology, Beijing, PR China.

†Resident, Department of Oral and Maxillofacial Surgery, Peking University School and Hospital of Stomatology, National Center of Stomatology, National Clinical Research Center for Oral Diseases, National Engineering Laboratory for Digital and Material Technology of Stomatology, Beijing, PR China.

‡Associate Professor, Department of Oral and Maxillofacial Surgery, Peking University School and Hospital of Stomatology, National Center of Stomatology, National Clinical Research Center for Oral Diseases, National Engineering Laboratory for Digital and Material Technology of Stomatology, Beijing, PR China.

§Associate Professor, Department of Oral and Maxillofacial Surgery, Peking University School and Hospital of Stomatology, National Center of Stomatology, National Clinical Research Center for Oral Diseases, National Engineering Laboratory for Digital and Material Technology of Stomatology, Beijing, PR China.

||Professor, Department of Oral and Maxillofacial Surgery, Peking University School and Hospital of Stomatology, National Center of Stomatology, National Clinical Research Center for Oral Diseases, National Engineering Laboratory for Digital and Material Technology of Stomatology, Beijing, PR China.

Funding: This study was supported by the Youth Fund of Peking University School and Hospital of Stomatology (grant number PKUSS20200110).

Conflict of Interest Disclosures: None of the authors have any relevant financial relationship(s) with a commercial interest.

Address correspondence and reprint requests to Dr An, Department of Oral and Maxillofacial Surgery, Peking University School and Hospital of Stomatology, No.22, Zhongguancun South Ave, Haidian District, Beijing 100081, PR China; e-mail: anjingang@126.com
Received May 28, 2021
Accepted July 24, 2021.

© 2021 The American Association of Oral and Maxillofacial Surgeons.

0278-2391

<https://doi.org/10.1016/j.joms.2021.07.029>

Bisphosphonates have been widely used as key components for managing patients with cancer having skeletal metastases. Bisphosphonate-related osteonecrosis of the jaw is uncommon, but it seriously affects the quality-of-life.¹ The American Association of Oral and Maxillofacial Surgeons (AAOMS) first introduced bisphosphonate-related osteonecrosis of the jaw systematically in 2007 and updated it as medication-related osteonecrosis of the jaw (MRONJ) because of other antiresorptive (denosumab) and antiangiogenic therapies that also induce osteonecrosis of the jaw.^{2,3}

Depending on the stage of MRONJ, current treatments include nonsurgical treatment (including oral antimicrobial rinses, hyperbaric oxygen, and teriparatide injection),^{4,5} conservative surgery, and extensive surgery.^{1,6,7} Although surgical treatment benefits patients with stage 2 and 3 MRONJ, the extent of surgery has not been settled.^{7,8} Furthermore, few studies have discussed the risk factor of recurrence after surgery.

In the present study, we analyzed the results of surgical treatment for stage 2 and 3 lower jaw lesions in patients treated intravenously (IV) with 4 mg zoledronic acid per month. The duration of medication over 18 months was identified as a prognostic factor related to recurrence.

Patients and Methods

This study was approved by the ethics committee of Peking University School and Hospital of Stomatology (No. PKUSSIRB-201949119) and was carried out in accordance with the Principles of the Declaration of Helsinki. The study population was composed of patients diagnosed with stage 2 and 3 MRONJ AAOMS, who were treated in the Department of Oral and Maxillofacial Surgery of our hospital from January 1, 2016 to December 31, 2020. To generate a homogeneous study population, we included patients with (1) current or previous IV treatment with 4 mg zoledronic acid per month, (2) lesions in the lower jaw that persisted for longer than 8 weeks, (3) no history of radiation therapy to the jaws or obvious metastatic disease to the jaws, and (4) minimum follow-up of 3 months after surgery. Patients who underwent debridement or sequestrectomy in other hospitals were excluded.

TREATMENT PROTOCOL FOR MRONJ

In accordance with the classification systems, our treatment protocol was as follows:

Preoperative Therapy

Patients were prescribed with gargling 0.12% chlorhexidine thrice a day. IV antibiotic prophylaxis

(cefuroxime sodium, 1.5 g) started 0.5 hours before surgery and was continued twice per day for 3 to 5 days.

Surgical Therapy

All operations were performed under general anesthesia.

For stage 2 lesions, sequestrectomy and saucerization were performed (Fig 1). In brief, unhealthy gingiva and sequestrum were removed. Then, the surrounding bony ridges were smoothed until viable bleeding bone was observed. The wounds were closely sutured without tension.

For stage 3 lesions, segmental mandibulectomy was performed to completely resect the lesions. The mandible defect was reconstructed through reconstruction plate and ipsilateral submandibular gland translocation, with or without submental perforator flap, as previously described (Fig. 2 and 3).⁹ Alternatively, the fibula free flap was vascularized if the patient's general condition could tolerate microsurgery surgery (Fig 4).

Postoperative Therapy and Follow-Up

A nasogastric feeding tube was used postoperatively for 1 to 2 weeks. During the follow-up period, all patients underwent examinations every month at the first 3 months after surgery.

Successful surgery was considered when complete mucosal healing was observed, and clinical symptoms are lacking 3 months after surgery. Recurrence was defined for symptoms that occurred within 3 months postoperatively, including dehiscence of soft tissue, exposure of necrotic bone, or infection of the surgical site. Biopsy of the bone was routinely performed in all cases to exclude metastatic disease of jaw.

VARIABLES AND DATA COLLECTION

The treatment outcome of MRONJ was considered the primary variable. The predictor variables were medical information, including age, gender, stage of lesions, duration of medication, duration of symptom, duration of symptom, drug holiday, trigger factors, chemotherapy, diabetes, and alcohol/tobacco.

STATISTICAL ANALYSIS

Statistical analysis was performed using SPSS v24.0 (IBM, Armonk, NY). The *t* test for continuous variables and χ^2 test for categorical variables were performed to analyze the differences between 2 groups. Multivariate logistic regression analysis was performed to identify the risk factors for MRONJ recurrence. Odds ratios (ORs) and 95% confidence intervals (CIs) were calculated. Enter method was used to analyze variables that contributed significant

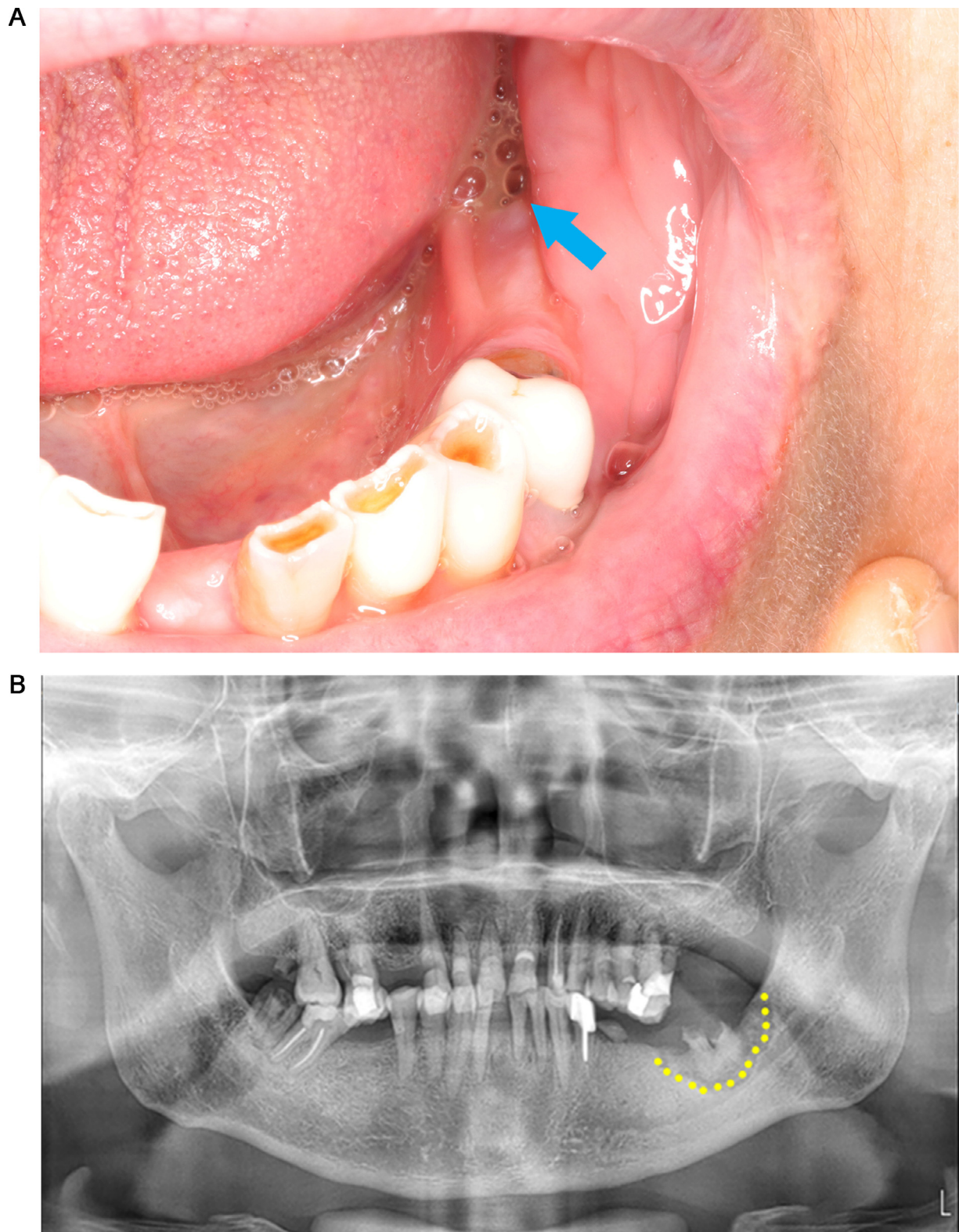


FIGURE 1. Sequestrectomy and saucerization for stage 2 lesion. *A*, Purulent secretion in the left posterior mandibular region. *B*, Panoramic radiographs before surgery showed osteonecrosis restricted to alveolar bone. *C*, Panoramic radiographs immediately after surgery showed surgical removal of necrotic bone.

Chen et al. Recurrence-Related Factors of MRONJ. J Oral Maxillofac Surg 2021.

C

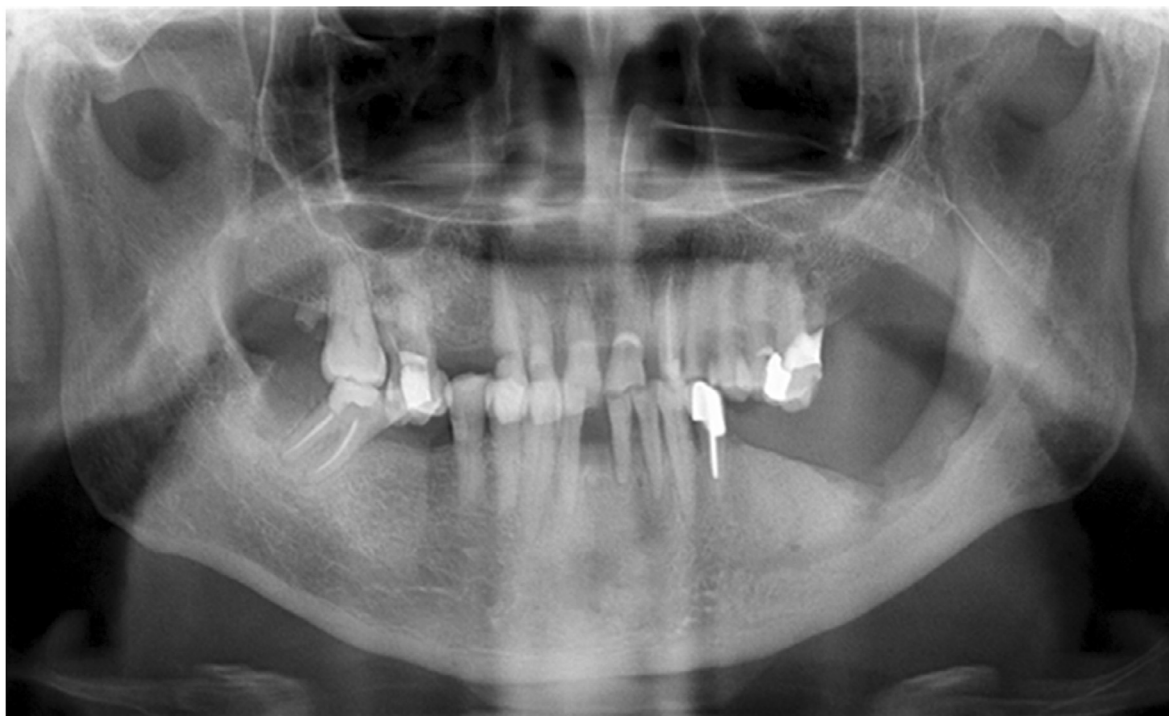

FIGURE 1. (Continued)

information to the model. Statistical significance was set at $P < .05$.

Results

GENERAL INFORMATION

A total of 126 patients with MRONJ underwent surgery from 2016 to 2020 at our hospital. Exactly 55 patient lesions located only at the upper jaw were excluded. We excluded 13 patients with a lesion located at the lower jaw and used other drugs instead of zoledronic acid. Exactly 58 patients (62 sites) met the inclusion criteria of this study. Five of these 58 patients also had upper jaw lesions. All these patients used zoledronic acid because of malignant tumor. The follow-up period ranged from 3 to 35 months (average, 10.5 months).

Exactly 33 sites were classified as stage 2, while 29 sites were classified as stage 3, as shown in [Table 1](#). Overall, 50 (80.6%) of the 62 MRONJ sites were successfully treated. Nine sites of stage 2 and 3 sites of stage 3 were diagnosed as recurrence after first surgery. Seven of 9 sites in stage 2 progressed to stage 3. Lesion enlarged in other cases of recurrence.

CLINICAL CHARACTERISTIC OF PATIENTS

Gender and Age

Exactly 39 females and 19 males (F/M ration, 2:1) in the study indicated a female predisposing factor. The

average age was 63.2 in the success group and 63.8 in the failure group ([Table 2](#)).

Stage of Lesions

Approximately 89.7% of stage 3 lesions and 72.7% stage 2 lesions were treated successfully. No significant difference was observed in the recurrence rate between these 2 stages ([Table 2](#)).

Duration of Medication and Symptoms

The average duration of medication in the success group was 16.9 ± 10.2 months (range: 5-48 months), which is significantly shorter than that of the recurrence group of 25.3 ± 11.8 months (range: 9-46 months). The duration of symptom in the success group was 7.9 ± 5.7 months, which is comparable with that in the recurrence group (9.6 ± 8.2 months) ([Table 2](#)).

Drug Holiday

No significant difference was observed in the drug holiday between the success group (9.7 ± 10.8 months) and recurrence group (9.1 ± 6.4 months) ([Table 2](#)).

Triggering Factors

Tooth extraction was the most common cause (61.3%) of MRONJ. Other trigger factors include periodontal or periapical disease, peri-implant disease, and denture trauma ([Table 2](#)).

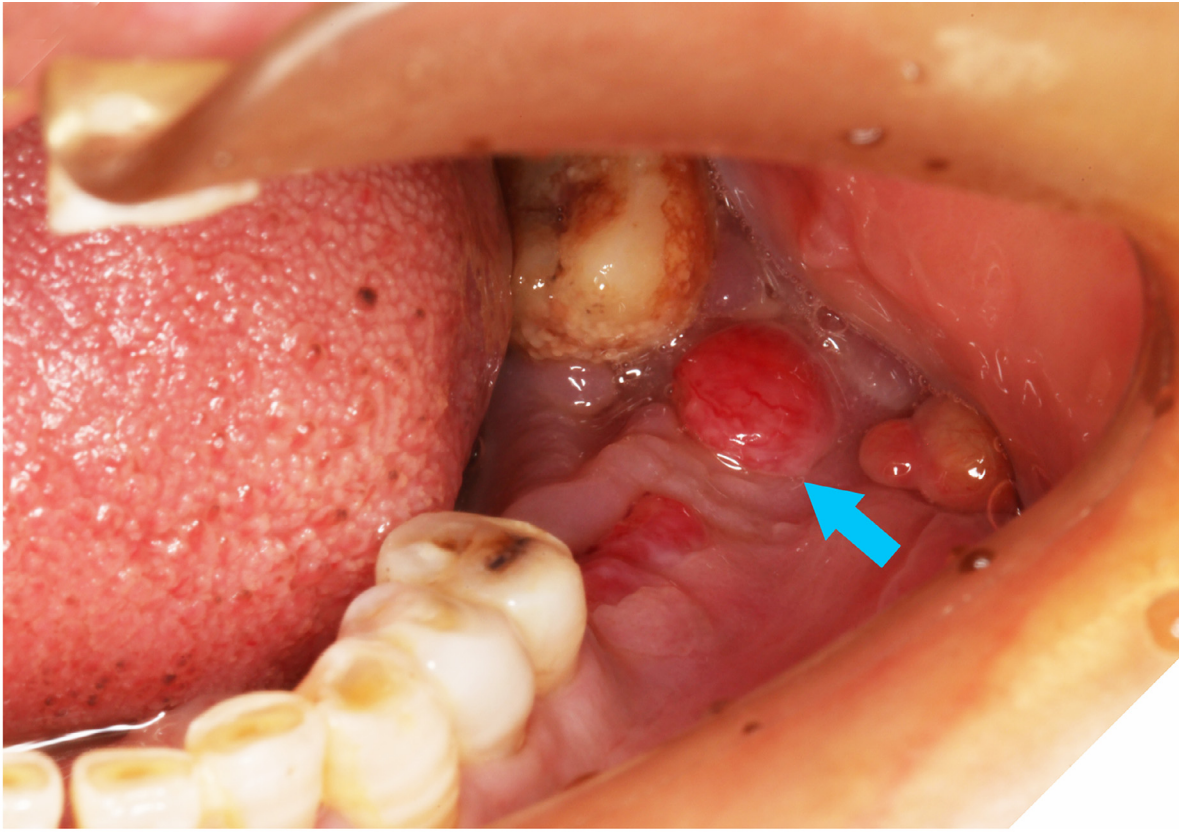
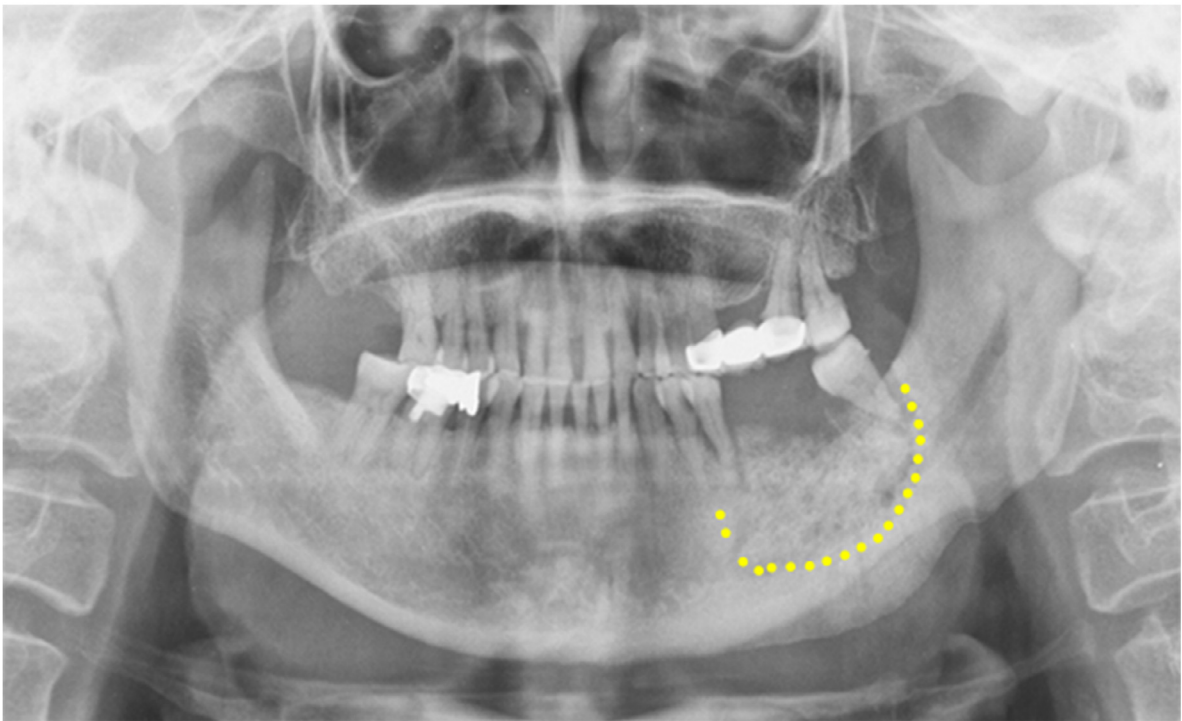
A**B**

FIGURE 2. Segmental mandibulectomy and reconstruction with a reconstruction plate for stage 3 lesion. A, Fistula in the left posterior mandibular region. B, Panoramic radiographs before surgery showed osteonecrosis extending beyond the region of alveolar bone. C, Panoramic radiographs immediately after surgery showed surgical removal of necrotic bone and reconstruction with a reconstruction plate.

Chen et al. Recurrence-Related Factors of MRONJ. J Oral Maxillofac Surg 2021.

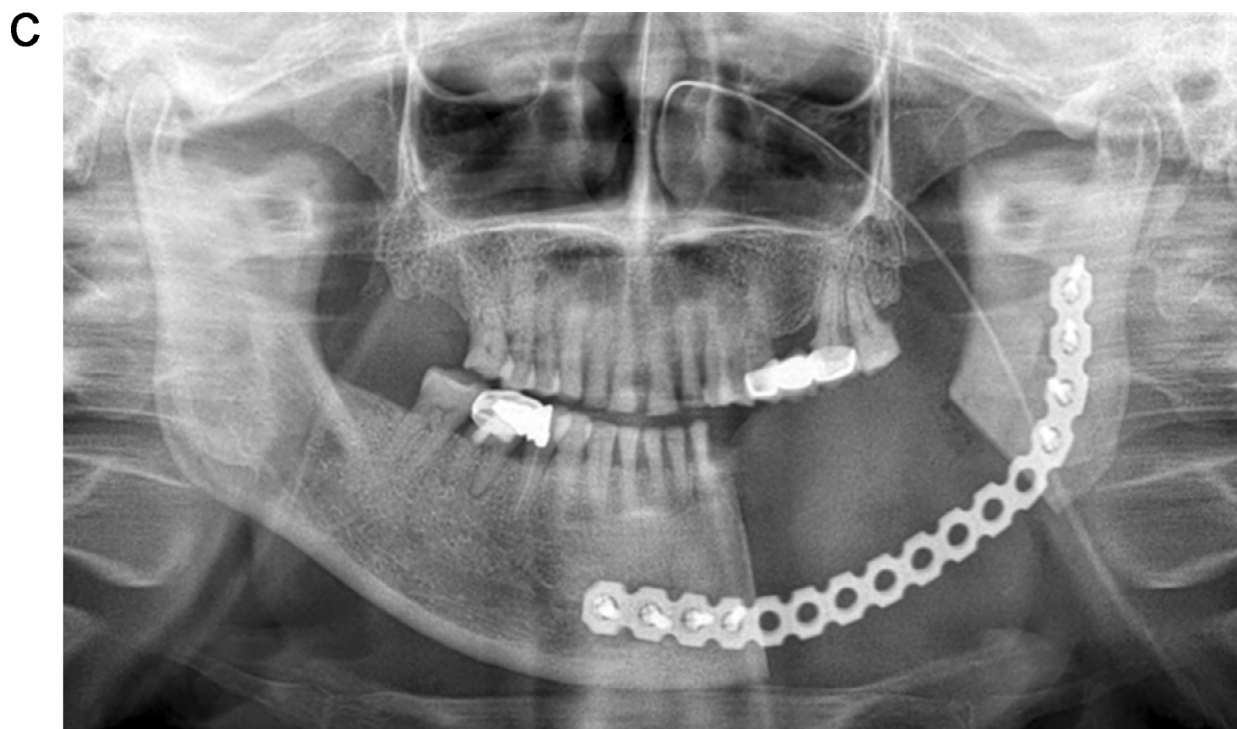

FIGURE 2. (Continued)

Other Variables

We further analyzed other variables, including chemotherapy, diabetes, alcohol, and tobacco. No significant difference was observed among these variables between the success and relapse groups (Table 2).

RISK FACTORS OF MRONJ RECURRENCE

Multivariate logistic regression analysis demonstrated that the duration of medication >18 months (OR = 7.346; 95% CI: 1.461-36.946; *P* = .016) was significantly correlated with recurrence (Table 3).

Discussion

The AAOMS 2014 position paper reported that the treatment for patients with MRONJ aims to eliminate pain, control infection of the soft and hard tissue, and minimize the progression or occurrence of bone necrosis. Although the management of MRONJ is widely studied, surgeons find it hard to determine the most appropriate treatment strategy. In the present study, we focused on patients with lesions in the lower jaw and underwent treated with IV zoledronic

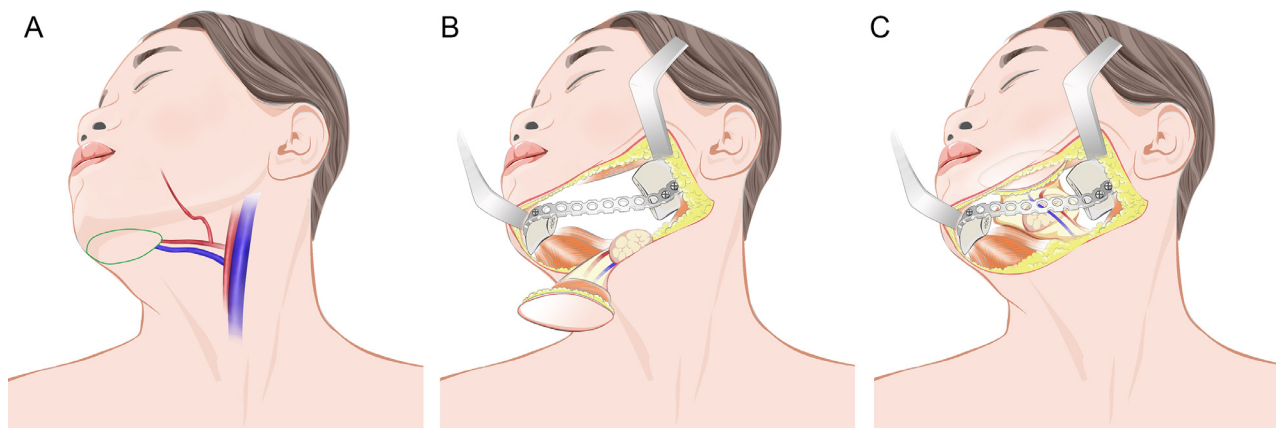


FIGURE 3. Schematic diagram of the submental perforator flap. A, Design of the submental perforator flap. B, Resection of the lesions and preparation of the submental perforator flap. C, Closure of intraoral soft tissue defects by using submental perforator flap.

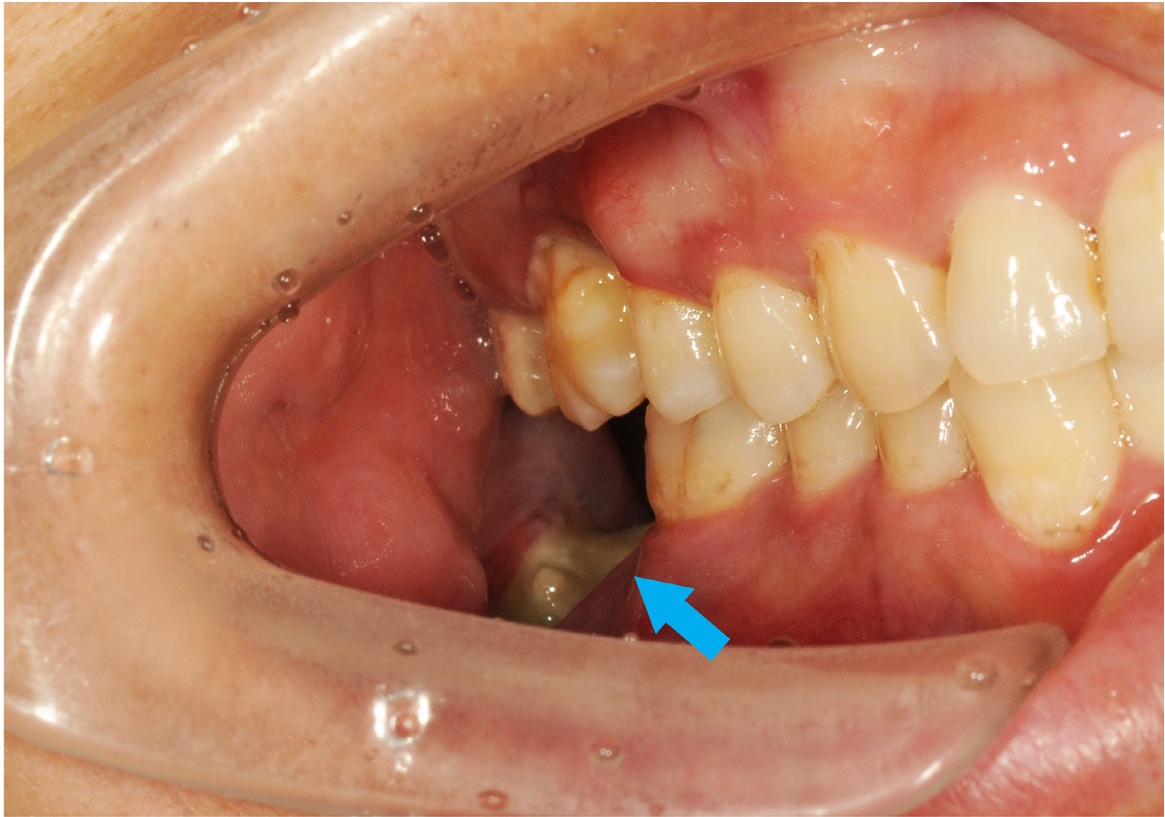
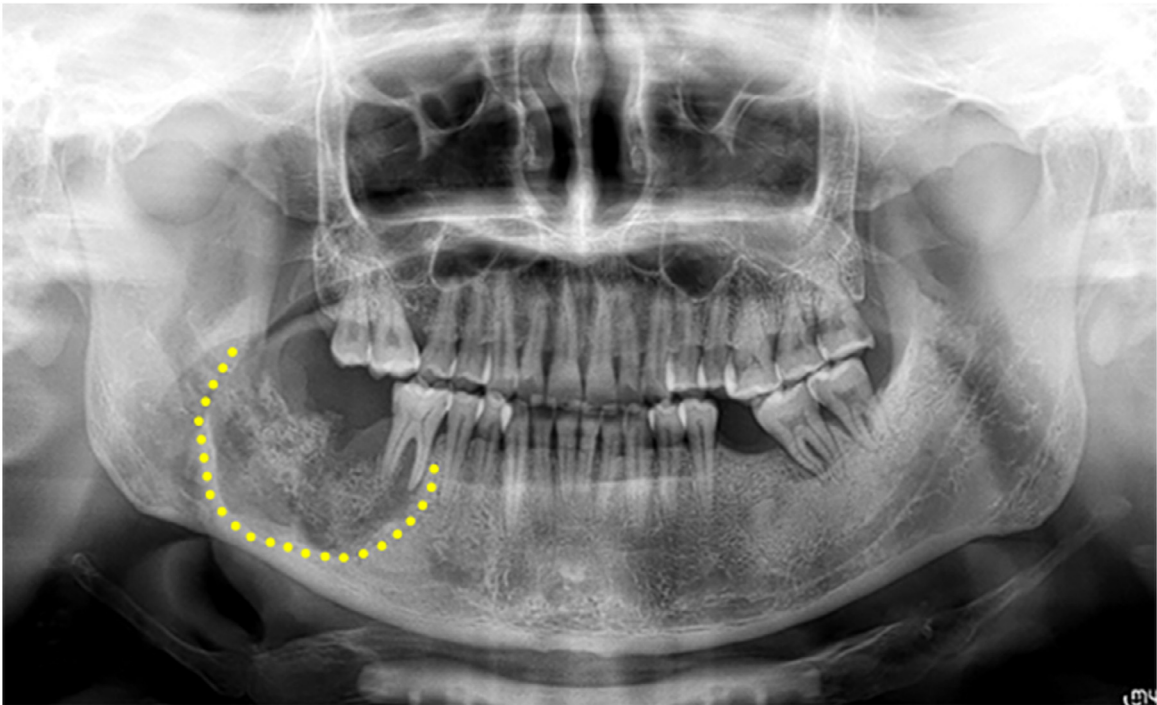
A**B**

FIGURE 4. Segmental mandibulectomy and reconstruction with vascularized fibula free flap. **A**, Necrotic bone exposed in the right posterior mandibular region. **B**, Panoramic radiographs before surgery showed osteonecrosis extending to the inferior border of mandible. **C**, Panoramic radiographs immediately after surgery showed surgical removal of necrotic bone and reconstruction with vascularized fibula free flap.

Chen et al. Recurrence-Related Factors of MRONJ. J Oral Maxillofac Surg 2021.

C

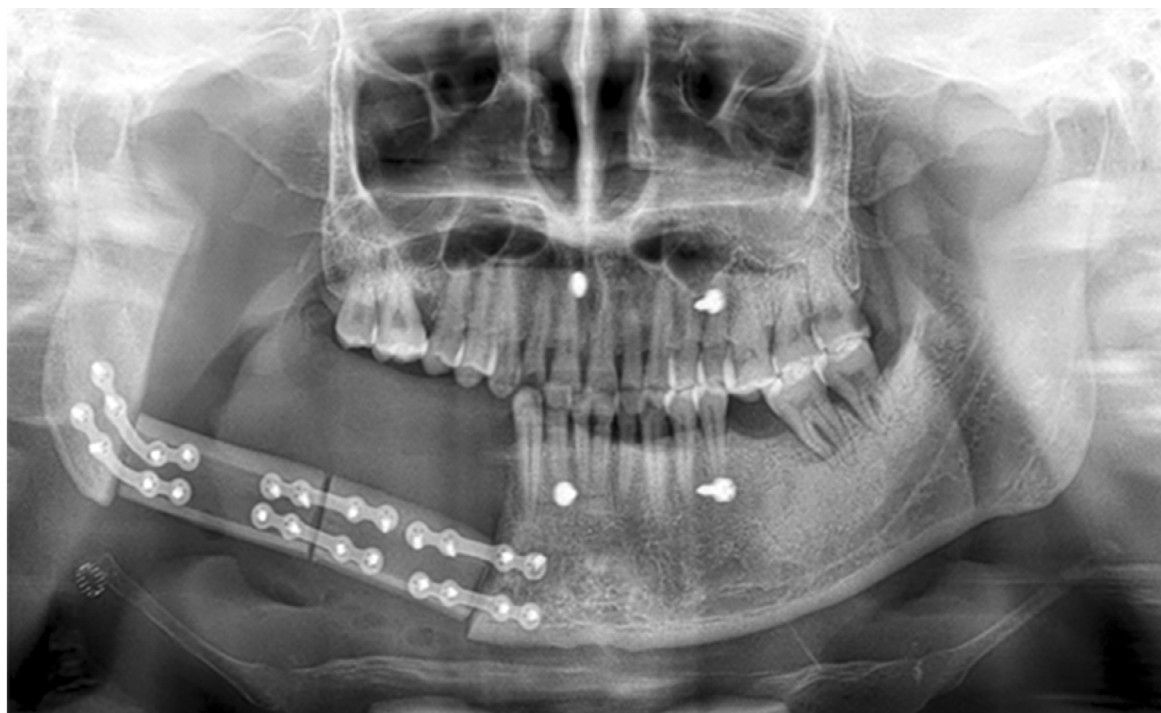


FIGURE 4. (Continued)

acid. The result showed that 80.6% of (50/62) of the 62 MRONJ sites achieved primary healing through extensive resection for stage 2 or 3 lesions. Besides, the duration of medication has not been previously

described as a prognostic factor in terms of recurrence in published literature.

Although a few studies had analyzed the factors that affect treatment outcome, the study population received different kinds of bisphosphonates.^{7,10} Bisphosphonates are classified as first-, second-, and third-generation, implying progressively high potencies.¹¹ Therefore, the type of drug may be a confounding factor that affects the treatment effect. Zoledronic acid is the most commonly used bisphosphonate in patients with MRONJ.¹²⁻¹⁵ In the present study, we analyzed a homogeneous population IV treated with 4 mg zoledronic per month and identified the duration of medication. This period is significantly longer in the recurrence group than the success group. Intravenous zoledronic (4 mg) is typically used for delaying or preventing skeletal-related events in patients with advanced cancer and bone metastases.¹⁶⁻¹⁹ The results showed that its use for over 18 months was a prognostic factor related to recurrence.

According to the guidelines of different association, people have reached a consensus on the stage-specific therapeutic strategies.²⁰ Typically, conservative treatment results in good outcomes at the early stages, and surgical treatment is recommended for the management of advanced stages. However, the surgical method for stage 2 and 3 remains controversial. Generally, 2 surgical methods, including minimally invasive or conservative surgical approach, have been studied. Different groups have different

Table 1. NUMBER OF SITES IN DIFFERENT SURGICAL METHODS.

Stage of MRONJ	Surgical Method	Number of Sites
2	Sequestrectomy and saucerization	33
3	① segmental mandibulectomy+ reconstruction plate + submandibular gland translocation	23
	② segmental mandibulectomy+ reconstruction plate + submandibular gland translocation + submental perforator flap	3
	③ segmental mandibulectomy+ vascularized fibula free flap	3

Chen et al. Recurrence-Related Factors of MRONJ. *J Oral Maxillofac Surg* 2021.

Table 2. STUDY VARIABLES GROUPED BY TREATMENT OUTCOME.

characteristic	Treatment outcome		P Value
	Success	Relapse	
Sex			.96
Female	31 (79.5%)	8 (20.5%)	
Male	15 (78.9%)	4 (21.1%)	
Age, year	63.2 ± 9.5	63.8 ± 8.2	.82
Stage			.08
2	24 (72.7%)	9 (27.3%)	
3	26 (89.7%)	3 (10.3%)	
Duration of medication, months	16.9 ± 10.2	25.3 ± 11.8	.02
Duration of symptom, months	7.9 ± 5.7	9.6 ± 8.2	.41
Drug holiday, months	9.7 ± 10.8	9.1 ± 6.4	.85
Trigger			.16
Tooth extraction	28 (73.7%)	10 (26.3%)	
Others	22 (91.7%)	2 (8.3%)	
Chemotherapy			.12
Yes	29 (72.5%)	11 (27.5%)	
NO	17 (94.4%)	1 (5.6%)	
Diabetes			.63
Yes	9 (90%)	1 (10%)	
No	37 (77.1%)	11 (22.9%)	
Alcohol			.37
Yes	1 (50%)	1 (50%)	
No	45 (80.4%)	11 (19.6%)	
Tobacco			.37
Yes	1 (50%)	1 (50%)	
No	45 (80.4%)	11 (19.6%)	

Data are expressed as *n* (%) or mean ± standard deviation.

The *t* test for continuous variables and χ^2 test for categorical variables were performed to analyze the differences between 2 groups.

Chen et al. Recurrence-Related Factors of MRONJ. J Oral Maxillofac Surg 2021.

definitions of conservative surgical treatment, resulting in heterogeneous results. Coropciuc et al¹² and Nisi et al^{21,22} defined conservative surgical treatment as sequestrectomy, soft tissue debridement and bone curettage, with 74.4 and 84.9% achieving complete mucosal healing, respectively. Hayashida et al⁷ defined conservative surgery as the removal of only the necrotic bone (ie, sequestrectomy), in which 44.7% achieved complete healing.

The other method is invasive or extensive surgery, which refers to marginal mandibulectomy or segmental resection. Favia²³ reported that 86.5% of stage 3 lesions showed complete healing through extensive surgery, and this result was similar to Hayashida's study with 86.8% complete healing rate. In a systematic review, Vanpoecke et al concluded that extensive bony resection up to the bleeding margins was more

Table 3. LOGISTIC REGRESSION ANALYSIS OF FACTORS ASSOCIATED WITH RELAPSE.

Variable	OR	95% CI	P
Age			
>63 years	0.549	0.116-2.593	.449
≤63 years	1 (reference)		
Stage			
3	0.168	0.026-1.074	.059
2	1 (reference)		
Drug holiday			
>9 m	2.744	0.469-16.072	.263
≤9 m	1 (reference)		
Duration of medication			
>18 m	7.346	1.461-36.946	.016
≤18 m	1 (reference)		
Chemotherapy			
Yes	3.316	0.546-20.142	.193
No	1 (reference)		
Diabetes			
Yes	0.423	0.042-4.226	.464
No	1 (reference)		
Alcohol/tobacco			
Yes	2.016	0.096-42.173	.651
No	1 (reference)		

Abbreviations: CI, confidence interval; OR, odds ratio.

Chen et al. Recurrence-Related Factors of MRONJ. J Oral Maxillofac Surg 2021.

efficient than a sequestrectomy for achieving full mucosal healing in the MRONJ stage 3.⁶

In the present study, patients underwent extensive surgery follow our protocol. In brief, sequestrectomy and saucerization were conducted for stage 2 lesions, and segmental mandibulectomy was performed for stage 3 lesions. Notably, the relapse rate was higher in stage 2 (27.3%) than in stage 3 (10.3%) lesions contrary to some studies that demonstrate better prognosis in stage 2 lesion.²²⁻²⁴ This high relapse in stage 2 lesion is supported by our clinical experience, although no statistically significant difference was found. The difference in relapse rate was related to surgical method. First, segmental mandibulectomy for stage 3 could be more effective to remove necrotic bone than sequestrectomy combined with saucerization for stage 2 lesions. The clinical appearance of bleeding bone was considered as margin for saucerization, and this condition may be not sufficient to remove unhealthy bone. Bone fluorescence technique is a useful tool to distinguish viable from necrotic bone.^{25,26} Histopathological analysis revealed a significantly decreased level of osteocytes and collagen type-I fibers in clinical vital bone compared with fluorescing bone.²⁷ Therefore, bone bleeding is probably not a reliable parameter to determine

the extent of the margins of osteonecrosis. Fluorescence-guided bone resection may offer a promising approach to distinguish necrotic bone from vital bone. Second, submandibular gland translocation with or without submental perforator flap or vascularized bone reconstruction was used to eliminate the dead space caused by mandibulectomy for stage 3 lesion. These methods could be more effective in promoting wound healing than a local mucoperiosteal flap in stage 2 lesions. Mucke et al introduced a mylohyoid muscle flap to provide additional tissue coverage in the surgical treatment of MRONJ.²⁸ In comparison with a mucoperiosteal flap, this double-layer closure technique remarkably reduced the recurrence rate of MRONJ. Ristow et al reported that 88% of the patients showed mucosal integrity 8 months after treated with mylohyoid muscle flap and recommended this technique as an option in the standard treatment protocol.²⁹

In conclusion, our results indicate that administration of IV zoledronic acid over 18 months may increase the risk of recurrence after extensive surgery in patients with MRONJ.

References

- Nicolatou-Galitis O, Schiodt M, Mendes RA, et al. Medication-related osteonecrosis of the jaw: definition and best practice for prevention, diagnosis, and treatment. *Oral Surg Oral Med Oral Pathol Oral Radiol* 127:117, 2019
- Ruggiero SL, Dodson TB, Fantasia J, et al. American Association of Oral and Maxillofacial Surgeons position paper on medication-related osteonecrosis of the jaw—2014 update. *J Oral Maxillofac Surg* 72:2014, 1938
- Advisory Task Force on Bisphosphonate-Related Osteonecrosis of the Jaws AAO, Maxillofacial S: American Association of Oral and Maxillofacial Surgeons position paper on bisphosphonate-related osteonecrosis of the jaws. *J Oral Maxillofac Surg* 65:369, 2007
- Freiberger JJ: Utility of hyperbaric oxygen in treatment of bisphosphonate-related osteonecrosis of the jaws. *J Oral Maxillofac Surg* 67:96, 2009
- Ohbayashi Y, Iwasaki A, Nakai F, Mashiba T, Miyake M: A comparative effectiveness pilot study of teriparatide for medication-related osteonecrosis of the jaw: daily versus weekly administration. *Osteoporos Int* 31:577, 2020
- Vanpoecke J, Verstraete L, Smeets M, Ferri J, Nicot R, Politis C: Medication-related osteonecrosis of the jaw (MRONJ) stage III: conservative and conservative surgical approaches versus an aggressive surgical intervention: a systematic review. *J Cranio-maxillofac Surg* 48:435, 2020
- Hayashida S, Soutome S, Yanamoto S, et al. Evaluation of the treatment strategies for medication-related osteonecrosis of the jaws (MRONJ) and the factors affecting treatment outcome: a multicenter retrospective study with propensity score matching analysis. *J Bone Miner Res* 32:2022, 2017
- Aljohani S, Troeltzsch M, Hafner S, Kaeppler G, Mast G, Otto S: Surgical treatment of medication-related osteonecrosis of the upper jaw: case series. *Oral Dis* 25:497, 2019
- Zhou W, Feng Z, An J, Wang H, Zhang Y: Combined reconstruction plate fixation and submandibular gland translocation for the management of medication-related osteonecrosis of the mandible. *Int J Oral Maxillofac Surg* 49:1584, 2020
- Choi NR, Lee JH, Park JY, Hwang DS: Surgical treatment of medication-related osteonecrosis of the jaw: a retrospective study. *Int J Environ Res Public Health* 17:1-9, 2020
- Cremers S, Drake MT, Ebetino FH, Bilezikian JP, Russell RGG: Pharmacology of bisphosphonates. *Br J Clin Pharmacol* 85:1052, 2019
- Coropciuc RG, Grisar K, Aerden T, Schol M, Schoenaers J, Politis C: Medication-related osteonecrosis of the jaw in oncological patients with skeletal metastases: conservative treatment is effective up to stage 2. *Br J Oral Maxillofac Surg* 55:787, 2017
- Klingelhoffer C, Zeman F, Meier J, Reichert TE, Ettl T: Evaluation of surgical outcome and influencing risk factors in patients with medication-related osteonecrosis of the jaws. *J Cranio-maxillofac Surg* 44:1694, 2016
- Feng Z, An J, Zhang Y: Factors influencing severity of medication-related osteonecrosis of the jaw: a retrospective study. *J Oral Maxillofac Surg* 79:1683-1688, 2021
- Van Poznak CH, Unger JM, Darke AK, et al. Association of osteonecrosis of the jaw with zoledronic acid treatment for bone metastases in patients with cancer. *JAMA Oncol* 7:246, 2021
- Limones A, Saez-Alcaide LM, Diaz-Parreno SA, Helm A, Bornstein MM, Molinero-Mourelle P: Medication-related osteonecrosis of the jaws (MRONJ) in cancer patients treated with denosumab vs. zoledronic acid: a systematic review and meta-analysis. *Med Oral Patol Oral Cir Bucal* 25:e326, 2020
- Raje N, Terpos E, Willenbacher W, et al. Denosumab versus zoledronic acid in bone disease treatment of newly diagnosed multiple myeloma: an international, double-blind, double-dummy, randomised, controlled, phase 3 study. *Lancet Oncol* 19:370, 2018
- Henry DH, Costa L, Goldwasser F, et al. Randomized, double-blind study of denosumab versus zoledronic acid in the treatment of bone metastases in patients with advanced cancer (excluding breast and prostate cancer) or multiple myeloma. *J Clin Oncol* 29:1125, 2011
- Fizazi K, Carducci M, Smith M, et al. Denosumab versus zoledronic acid for treatment of bone metastases in men with castration-resistant prostate cancer: a randomised, double-blind study. *Lancet* 377:813, 2011
- Ramaglia L, Guida A, Iorio-Siciliano V, Cuzzo A, Blasi A, Sculean A: Stage-specific therapeutic strategies of medication-related osteonecrosis of the jaws: a systematic review and meta-analysis of the drug suspension protocol. *Clin Oral Investig* 22:597, 2018
- Nisi M, Karapetsa D, Gennai S, Ramaglia L, Graziani F, Gabriele M: Conservative surgical treatment of medication related osteonecrosis of the jaw (MRONJ) lesions in patients affected by osteoporosis exposed to oral bisphosphonates: 24 months follow-up. *J Cranio-maxillofac Surg* 46:1153, 2018
- Nisi M, La Ferla F, Karapetsa D, et al. Conservative surgical management of patients with bisphosphonate-related osteonecrosis of the jaws: a series of 120 patients. *Br J Oral Maxillofac Surg* 54:930, 2016
- Favia G, Tempesta A, Limongelli L, Crincoli V, Maiorano E: Medication-related osteonecrosis of the jaw: surgical or non-surgical treatment? *Oral Dis* 24:238-242, 2018
- Bodem JP, Schaal C, Kargus S, et al. Surgical management of bisphosphonate-related osteonecrosis of the jaw stages II and III. *Oral Surg Oral Med Oral Pathol Oral Radiol* 121:367, 2016
- Tomo S, da Cruz TM, Figueira JA, Cunha JLS, Miyahara GI, Simionato LE: Fluorescence-guided surgical management of medication-related osteonecrosis of the jaws. *Photodiagn Photodyn Ther* 32:102003, 2020
- Aljohani S, Gaudin R, Weiser J, et al. Osteonecrosis of the jaw in patients treated with denosumab: a multicenter case series. *J Cranio-maxillofac Surg* 46:1515, 2018
- Wehrhan F, Weber M, Neukam FW, Geppert CI, Kesting M, Preidl RHM: Fluorescence-guided bone resection: a histological analysis in medication-related osteonecrosis of the jaw. *J Cranio-maxillofac Surg* 47:1600, 2019
- Mucke T, Koerdt S, Jung M, et al. The role of mylohyoid flap in the treatment of bisphosphonate-related osteonecrosis of the jaws. *J Cranio-maxillofac Surg* 44:369, 2016
- Ristow O, Ruckschloss T, Bodem J, et al. Double-layer closure techniques after bone surgery of medication-related osteonecrosis of the jaw—a single center cohort study. *J Cranio-maxillofac Surg* 46:815, 2018